

Emerging Endovenous Therapies

A look at the new generation of thermal tumescent and nonthermal nontumescent technologies and their best applications.

BY STEVE ELIAS, MD, FACS

“So we beat on, boats against the current, borne back ceaselessly into the past.”

*—F. Scott Fitzgerald,
“The Great Gatsby”*

Currently, all endovenous therapies for axial incompetence (great saphenous vein [GSV], small saphenous vein, anterior accessory GSV, etc.) can be divided into two types: thermal tumescent (TT) and nonthermal nontumescent (NTNT) (Table 1). The TT types of endovenous ablation have been the most studied and have demonstrated excellent efficacy and safety. Most importantly, they are durable and positively affect patients’ quality of life.¹ There is no question that they have revolutionized the management of venous disease. However, it is the nature of medicine or surgery to always evolve.

Recently, a new generation of technology has emerged in the forms of NTNT methods of endovenous ablation, along with new methods of TT ablation. Although much newer, these technologies have shown to be promising techniques for endovenous ablation. One should never dismiss new technologies until enough data have been obtained and the technology has matured. These technologies should be evaluated with the same attitude that was applied to laser and radiofrequency ablation in the early 2000s. The practicing vein specialist should be familiar with new technologies and decide how they are best applied for optimal patient outcomes. This article reviews both new TT and NTNT technologies.

TT THERAPY

Steam Ablation

Although the great majority of new technologies have been in the NTNT category, steam ablation is the newest of the TT technologies. Van de Bos² reported

TABLE 1. THE TWO TYPES OF ENDOVENOUS ABLATION

TT	NTNT
Radiofrequency	Mechanochemical ablation
Laser	Glue
Steam	Polidoconol endovenous microfoam
	V-Block

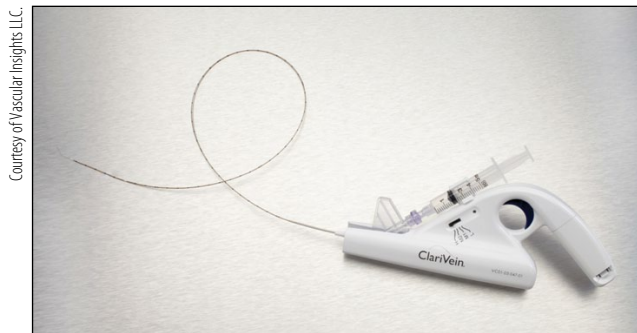the initial results of steam ablation in 2011. Subsequent authors have also documented its efficacy.³ Steam works by supplying approximately 60 joules/cm per pulse of steam to the vein, which is in the same range as radiofrequency or laser ablation. Of course, by giving more than one pulse of steam to a vein segment, greater energy can be delivered (SVS system, Cerma SA, Archamps, France). The amount of energy delivered is determined by vein diameter (one, two, or three pulses). Using this protocol, a 6-month 96% occlusion rate has been achieved.³ Obviously, longer follow-up is needed.

Because steam requires tumescence, it has some theoretic advantages: the solution cools to water so no chemical (sclerosant) or foreign body (eg, glue) is left in the patient, and steam can turn corners. Its best application may be in the treatment of branch varicosities where the risk of pigmentation may be less than sclerotherapy. As with all endovenous therapies, it is percutaneous with a short procedure time. Quality of life is also improved as with any successful axial vein occlusion.

NTNT THERAPY

Mechanochemical Ablation

The NTNT technology that has the longest follow-up experience thus far is mechanochemical ablation



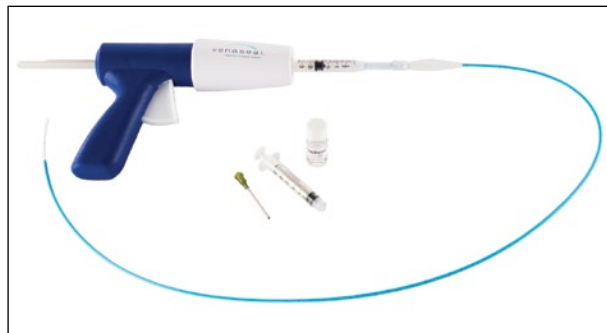
Courtesy of Vascular Insights LLC.

Figure 1. The ClariVein occlusion catheter.

(ClariVein, Vascular Insights LLC, Quincy, MA). Initial studies began in 2009 and were reported in 2011.⁴ The device consists of a rotating wire (3,500 rpm) that abrades the venous endothelium. At the same time, a liquid sclerosant is injected and embolized into the vein (sodium tetradecyl sulfate or polidoconol) (Figure 1). The two actions together, mechanical and chemical embolization, lead to vein occlusion. Local anesthesia is used at the insertion site, no tumescence is required, and the patient only feels a slight vibration of the rotating wire. Follow-up of patients at > 2 years reveals a 96% occlusion rate and sustained quality of life improvement.⁵ The device has been used in the small saphenous vein⁶ and has been compared to radiofrequency ablation.⁷ Complications are minimal; deep vein thrombosis occurs in < 0.5% of cases, and no nerve or skin injury has been reported because the technology is nonthermal. The advantages in certain clinical settings of this and other NTNT techniques will be discussed later in the Summary.

Cyanoacrylate Glue

Cyanoacrylate glue (VenaSeal, Saphen, Inc., Morrisville, NC) is delivered through a specifically designed catheter that doesn't allow the glue to mature within it but rather in the lumen of the vein (Figure 2). When the glue mixes with the blood or plasma, it polymerizes. This causes an acute inflammatory reaction, ultimately leading to lumen occlusion. Initial studies⁸ started extrusion of the glue 2 cm from the saphenofemoral junction (SFJ). This led to some extrusion into the common femoral vein. It is now recommended to begin treatment 5 cm from the SFJ. Proebstle et al⁹ reported results for 70 patients in seven European centers at 1 year with a 94% occlusion rate. This was accompanied by venous clinical severity score improvement as well. It is interesting to note that no compression was used posttreatment, and the amount of glue used was quite low (1.5 mL for an entire treatment). The glue does not



Courtesy of Saphen, Inc.

Figure 2. The VenaSeal closure system.



Courtesy of BTG International, Inc.

Figure 3. Varithena polidoconol injectable foam.

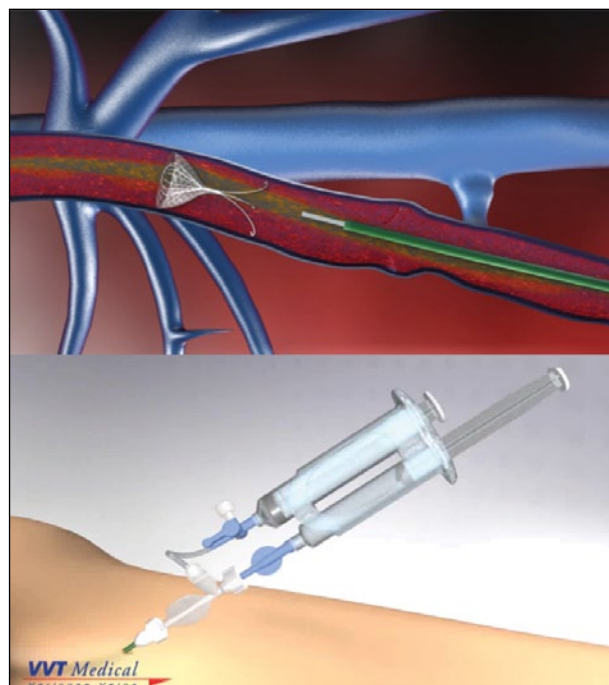
completely degrade and can be found in the vein after 1 year. Whether this is important or not remains to be determined. The 1-year results are promising, and the lack of posttreatment compression may be appealing to patients.

Polidoconol Endovenous Microfoam

Polidoconol endovenous microfoam (Varithena, BTG International Inc., West Conshohocken, PA) is a proprietary mixture of polidoconol, O₂, and CO₂ in a special canister that produces uniform foam (Figure 3). This is delivered percutaneously without tumescence into the vein. Studies have been ongoing for 10 years as the product required approval from the US Food and Drug Administration (FDA) as a drug and not as a device. It

was recently approved by the FDA in December 2013 and should be available by April or May 2014.

Multiple studies have occurred over the years, the most recent being the VANISH II trial results, which were reported at the American Venous Forum annual meeting in February 2014. The primary endpoint of the study was patient-reported outcomes called “VVSymQ,” a new FDA-approved quality-of-life measure. Other endpoints studied were independent physician photographic assessment of appearance (IPR-V3), patient-reported assessment of varicose veins appearance (PA-V3), and occlusion rates. It is interesting that although occlusion rates are lower than with other endovenous technologies (approximately 85%), quality-of-life improvement still occurs and improvement is significant. The improvement of patients’ quality of life is very important and really is the reason a vein procedure is performed—to help the patient, not just to occlude a vein. Of note, there were no pulmonary emboli and no cerebrovascular events, deep vein thrombosis rates were low (1.1%–1.7%), and thrombus extension into the deep system was 2.9% with subsequent complete resolution. Some patients



Courtesy of VWT Medical Ltd.

Figure 4. The V-Block occlusion device.

When one surveys the endovenous ablation landscape in 2014, there are many good choices to be found.

had concomitant treatment of their branch varicosities. Polidoconol endovenous microfoam should be commercially available in the next few months.

V-Block

The newest NTNT technology is V-Block (VVT Medical Ltd, Kfar Saba, Israel). The technique involves the release of an occlusion device at the SFJ and installation of a liquid sclerosant through a dual-syringe system (Figure 4). The occlusion device is a conical nitinol filter covered by a thin membrane of polytetrafluoroethylene similar to an inverted vena cava filter. The V-Block inner element acts as a scaffold for thrombus, preventing migration and allowing the thrombus to be encapsulated by endothelium. The dual-syringe system simultaneously aspirates blood, collapsing the vein, and instills a liquid sclerosant. One can conceptualize this technique as an internal SFJ ligation and enhanced GSV sclerotherapy into a collapsed vein.

A preclinical study in sheep was recently reported.¹⁰ Initial trial results in humans were reported by Dr. Ralf Kolvenbach at the 2013 VEITHsymposium and show similar results with early occlusion rates > 90%.¹¹ Fifty patients were studied, and 46 were followed to an average of 4.6 months. There was 100% occlusion at this early stage. No deep vein thrombosis was reported, and one patient experienced superficial thrombophlebitis. This device is still in very early development, and further studies are planned.

SUMMARY

When one surveys the endovenous ablation landscape in 2014, there are many good choices to be found. Technologies can be divided into TT or NTNT types, and each type has advantages in certain clinical or anatomic situations. The complication rates are relatively low for all of these. Laser and radiofrequency ablation have excellent long-term results but require the use of tumescence, which adds to patient procedural discomfort, and for a new physician, it is the longest part of the learning curve. Having said this, I believe these are very good techniques. There is the

theoretical risk of nerve or skin injury with TT technologies, but in the modern era of endovenous ablation, these are minimal as our training methods have improved. In contrast, thus far, there has been no nerve injury reported with any of the NTNT technologies. When evaluating these choices, perhaps the unique place for TT technologies is in larger veins, postthrombotic recanalized veins, or patients with elevated body mass index. NTNT techniques are perhaps best used with average-to-small-size veins, small saphenous veins, below-the-knee GSV, and retrograde to the malleolus in ulcer patients where it is difficult to place adequate tumescence. The future is heading toward NTNT ablation technology, but today's vein specialists need to be facile with both and use each type when the right situation arises. We are at an exciting time for endovenous ablation. Five years from now, probably 60% of veins will be treated with NTNT and 40% by TT. Or said another way:

*"Time will tell just who fell
And who's been left behind
When you go your way and I go mine"*

–Bob Dylan,
*"Most Likely You Go
Your Way and I'll Go Mine"*

Steve Elias, MD, FACS, is Director, Vascular Surgery Vein Programs, Columbia University Medical Center in New York. He has disclosed that he is a consultant to Vascular Insights and Covidien. Dr. Elias may be reached at (201) 894-3252; veininnoventions@aol.com.

1. Proebstle TM, Alm J, Gockeritz O, et al. Three year European follow-up of endovenous radiofrequency-powered segmental thermal ablation of the great saphenous vein with or without treatment of calf varicosities. *J Vasc Surg.* 2011;52:1-7.
2. Van den Bos. Proof of principle study of steam ablation as novel thermal therapy for saphenous varicose veins. *J Vasc Surg.* 2011;53:181-186.
3. Mlosek RK, Wozniak W, Gruszecki L, et al. The use of a novel method of endovenous steam ablation in treatment of great saphenous vein insufficiency: own experiences. *Phlebology.* 2014;29:58-65.
4. Elias S, Raines J. Mechanochemical tumescenceless endovenous ablation: final results of the initial clinical trial. *Phlebology.* 2012;27:67-72.
5. Elias S, Lam YL, Wittens CHA. Mechanochemical ablation: status and results. *Phlebology.* 2013;28(suppl 1):10-14.
6. Boersma D, van Eekeren RR, Werson DA, et al. Mechanochemical endovenous ablation of small saphenous vein insufficiency using the Clarivein device: one year results of a prospective series. *Eur Journal Vasc Endovasc Surg.* 2012;45:299-304.
7. Van Eekeren RR, Boersma D, Konijn V, et al. Prospective pain and early quality of life after radiofrequency ablation and mechanochemical endovenous ablation of incompetent great saphenous veins. *J Vasc Surg.* 2012;57:445-450.
8. Almeida JL, Javier JJ, MacKay E, et al. First human use of cyanoacrylate adhesive for treatment of saphenous vein incompetence. *J Vasc Surg: Venous Lymph Disord.* 2013;1:174-180.
9. Proebstle T, Alm J, Gockeritz O, et al. One year follow up of the European Multicenter Study on cyanoacrylate embolization of incompetent great saphenous veins. International Union of Phlebology World Meeting; September 8–13, 2013; Boston, MA.
10. Farber A, Belenky A, Malikova M, et al. The evaluation of a novel technique to treat saphenous vein incompetence: preclinical animal study to examine safety and efficacy of a new vein occlusion device. *Phlebology.* 2014;29:16-24.
11. Kolvenbach RR. A novel approach to closing the great saphenous vein: V-Block trial. Presented at the 2013 VEITHsymposium; November 19, 2013; New York, NY.